

Technological aspects in manufacturing of aesthetic prosthetic restorations with metal infrastructure

By Viorel Stefan Perieanu

Technological aspects in manufacturing of aesthetic prosthetic restorations with metal infrastructure

Andreea Angela Stetiu¹, Ana-Georgia Martinas², Viorel Stefan Perieanu³, Mihai Burlibasa, Mircea Popescu³, Oana Elena Amza³, Madalina Perieanu³, Liliana Burlibasa⁴, Vali Cătălina Matei³, Bogdan Alexandru Dimitriu³

¹"Lucian Blaga" University of Sibiu, Romania

²Private Practice, Bucharest, Romania

³"Carol Davila" University of Bucharest, Romania

⁴Faculty of Biology, University of Bucharest, Romania

¹
Corresponding authors:

Viorel Stefan Perieanu, e-mail: viorelperieanu@yahoo.com

Abstract

Restoring the morphology and functionality of dental arches affected by carious lesions and/or edentations using fixed prosthetic restorations has been a continuous challenge for dentists. Porcelain fused to metal prosthetic restorations using lost wax technique or modern digital methods have proven to be a useful tool in restoring aesthetics and mastication, things that lead to the social reintegration of patients. The natural aspect of the prosthetic restoration depends on the talent and inspiration of the dental technician as the art of layering of ceramic masses cannot be surpassed by new emerging technologies.

Keywords: lost wax, porcelain fused to metal, CAD/CAM

INTRODUCTION

Complete physiognomic prosthetic restorations with metal infrastructure are mixed prosthetic pieces, being made up of a metal component that ensures mechanical resistance and a physiognomic component, in our case we are talking about ceramic masses, which completely cover the metal component. These

prosthetic restorations are also known as dental bridges and are represented by the following component parts: the pontic (for the missing tooth/teeth) and the retainers/crowns (placed on prosthetic abutments) [1-3].

PURPOSE

Manufacturing porcelain fused to metal dental bridges requires a very good collaboration between the clinical department represented by the dental office and the technical department represented by the dental laboratory. In fact, it is about the dental medical team made up of the dentist and the dental technician.

The metallic infrastructure of prosthetic restoration can be obtained either by the classic method (the lost wax technique) or with the help of CAD-CAM digital technologies. Thus, the purpose of this material is to exemplify the obtaining of porcelain fused to metal prosthetic restorations both by the classic method and by the modern digital method.

MATERIAL AND METHOD

In this material, 2 cases of obtaining porcelain fused to metal prosthetic restorations are presented. In the first case, the metal framework was obtained using the lost wax technique, classic method, and in the second case, the metal infrastructure was made with the help of digital technologies, through the CAD-CAM method. In both situations, metal infrastructures were plated with ceramic masses for physiognomic purposes.

CASE PRESENTATION

Clinical case No. 1

A 50-year-old patient presented to the dental office for restoring of an edentulous space in the posterior area of mandible, caused by the loss of teeth 3.5 and 3.6 following extensive carious lesions. Due to the massive destruction caused by the carious processes, it was decided to extract teeth 3.5 and 3.6, and to make a dental bridge using teeth 3.4 and 3.7 as abutments. Following the clinical examination, a fixed porcelain fused to metal dental bridge obtained using the lost wax technique, using teeth 3.4 and 3.7 as abutments, was chosen as a therapeutic solution. After establishing the diagnosis and developing the treatment plan, the abutment teeth were

prepared. The functional impression was made using the two-step technique in a standard impression tray, using addition silicone impression materials in double consistencies, putty and light body. The impression of the opposing teeth was made in a standard impression tray using condensation silicone material of putty consistency. In the same clinical stage, the occlusal relationship was recorded using a silicone material (Figure 1).



FIGURE 1. Mandibular functional impression and the impression of maxillary arch.

After setting, the impressions were washed and decontaminated by immersion in a chemical solution with antimicrobial action, according to manufacturer recommendation. The working model was cast with type IV dental stone using Pindex technology, while the maxillary impression was cast in one piece also with type IV dental stone. Maxillary and mandibular model were mounted using an articulator based on the occlusal record (Figure 2).

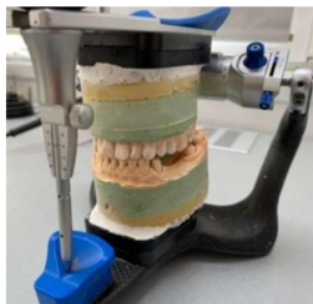

FIGURE 2. Maxillary and mandibular models mounted in the articulator.

On the working model the dental technician designs the wax-pattern for metallic infrastructure. The wax-pattern is then prepared for investing by applying wax sprue rods similar to Bego's rapid-wax-system (Figure 3).




FIGURE 3. Preparing the wax-pattern for investing. Applying wax sprue rods (left), applying the wax pattern on the cone of the crucible former (right).

After investing the wax-pattern the mold was placed in a burnout furnace to remove the wax (lost wax technique) and to obtain the thermal expansion of the investing material. The Ni-Cr dental alloy was inserted into the mold using an automatic centrifugal casting machine. The cast was de-vested, sandblasted, separated from the sprue rod with a cut-off disc. The metallic framework was trimmed and the outer surface was smoothed using abrasive burs and stones. The framework was checked on the working model and the thickness of the metal was measured using a professional caliper (Figure 4).



FIGURE 4. The final aspect of metallic framework on the working model (left).

Checking the thickness of the dental alloy using a professional caliper.

The final technological stage was represented by veneering the metallic component with ceramic masses to give prosthetic restoration a natural aspect (Figure 5).

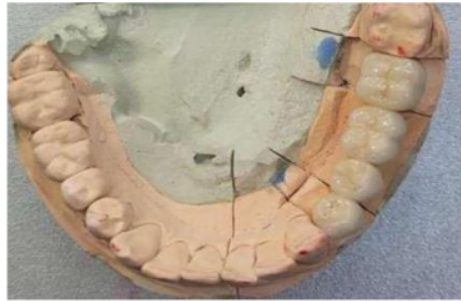


FIGURE 5. The final aspect of prosthetic restoration after applying the glaze, occlusal view.

Clinical Case No. 2

A 30-year-old patient presented himself in the dental office with discolorations at the level of upper front teeth, accusing problems of changing the physiognomy in the upper maxillary frontal area. 2-3 years ago, the patient was prosthetically rehabilitated in this region, with the help of a metal-acrylic fixed prosthetic restoration. Later, the patient wanted to exchange the metal-acrylic prosthetic restoration with a porcelain fused to metal prosthetic restoration, using the same abutment teeth. In this case, the metal infrastructure was made with the help of CAD-CAM digital technologies.

First, the dentist took the functional impression with an addition silicone material in a double consistency: putty and light body. The impression of the opposing teeth was made with condensation silicone of putty consistency. Also on this clinical stage, the occlusal relationship was recorded with the help of a fast-setting addition silicone. As in the previous case, these impressions were washed and decontaminated. A sectional model from type 4 dental stone was obtained for maxillary using the functional impression.

The maxillary and mandibular models, the abutment teeth and the occlusal record were scanned to obtain the virtual image of the clinical case. All images were processed using the Exocad program (Figure 6).

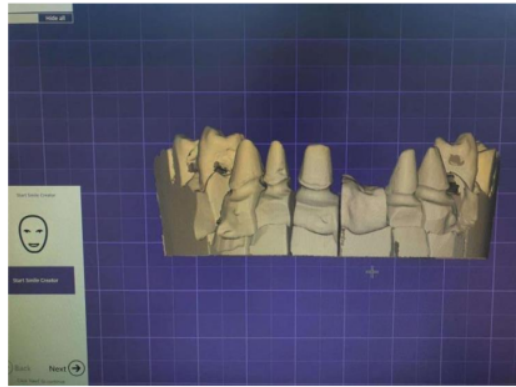


FIGURE 6. The virtual image of abutment teeth was checked at the end of the scanning process.

Following the specifications from laboratory sheet, sent from the dental office, the dental technician set the space for luting cement for 0.15 mm over the hole surface of abutments and the marginal line of abutment is set (Figure 7).

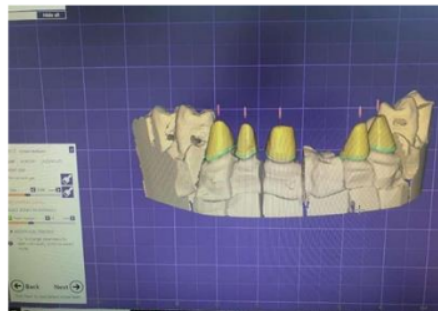


FIGURE 7. Setting the working parameters.

Another step was to create the design of copings based on the settings imposed by the configuration of the prosthetic restoration. The minimum thickness of the metal infrastructure was set to 0.6 mm, because after processing it with specific burs and stones, a thickness of approximately 0.4-0.5 mm will be reached (Figure 8).

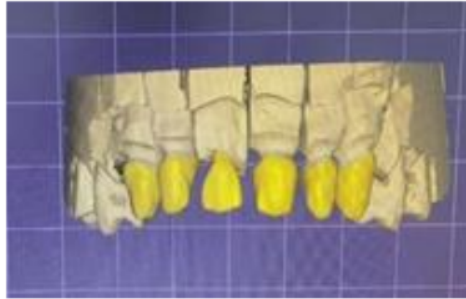


FIGURE 8. The design of metallic copings.

In the final design stage, connectors were automatically placed between copings by the program. Their position must optimize the final design of the metallic framework, to provide a special aesthetic and increased structural strength (Figure 9).

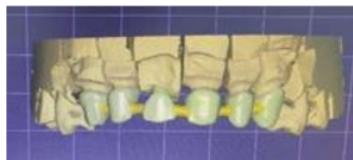


FIGURE 9. Connectors added by design program.

When the design was complete, the virtual image was sent to milling machine to obtain the metallic framework. The metal structure obtained was checked on the functional mandibular model, without prior adaptation or interventions. Thus, the errors that could have occurred if the classic lost wax technique were avoided (Figure 10).



FIGURE 10. The metallic framework fitted on the working model.

After the clinical try-in of metallic framework, the dental technician will apply porcelain on the surface of the dental alloy to obtain an aesthetic appearance (Figure 11).

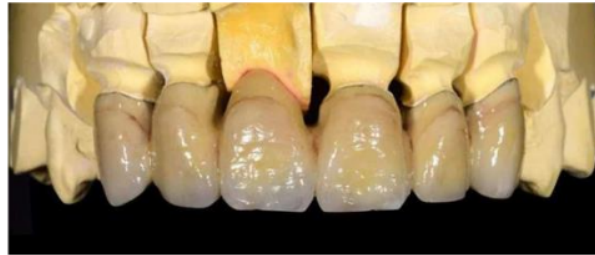

FIGURE 11. The final aspect of porcelain fused to metal prosthetic restoration.

DISCUSSIONS

Restoring the morphology and functionality of dental arches affected by carious lesions and edentations using fixed prosthetic restorations has been a continuous challenge for dentists. The development of new materials and technologies for their use has changed over time the approach to the previously mentioned clinical situations [5]. Restoring functionality has mastication and aesthetics as its main objectives, the importance of each being determined by the area of the arch that needs to be restored [6]. Mainly, the lateral area requires the restoration of the masticatory function as a priority, while the frontal area focuses primarily on restoring the aesthetic function [7].

The use of porcelain fused to metal restorations achieves a compromise for the two functions that require to be restored. The metal component ensures a reliable support where the masticatory forces present the highest values, namely at the level of the occlusal surfaces of the lateral teeth. At the same time, the ceramic masses with which the metal infrastructures are veneered recreate the aesthetic appearance of the restored teeth. At the same time, covering the metal component leads to limiting the contact between it and the adjacent soft tissues, which in the case of Ni-Cr or Co-Cr alloys, alloys with components that can cause allergic reactions, limits unwanted reactions for patients sensitive to such chemical elements.

The manufacturing of the metal component through the lost wax technique allows the dental technician to customize the clinical case based on the accumulated experience, adapting the future restoration according to the size of the abutment teeth and the edentulous spaces [8,9]. All of this is done with affordable equipment which has shown its effectiveness over time [5]. At the same time, the metal component can also be made using digital workflows [9,10]. The use of such technologies allows a superior control of restorations at the marginal level but also of the thickness of the metal component [11,12]. This optimizes the ratio between the aesthetics of the final restoration and its mechanical strength. The size of the metal component is reduced and at the same time the space for the physiognomic component is increased [13]. Thus, the aesthetic aspect of the restoration is improved without undermining its mechanical strength [14,15].

CONCLUSIONS

Porcelain fused to metal fixed prosthetic restorations represent an affordable and successful oral rehabilitation option, which quickly restores the functions of the dento-maxillary system. These prosthetic works are of particular importance because they were designed to be applied to teeth with low height, teeth with slight malposition, bruxism, teeth with small mesiodistal diameter teeth in which the destruction the coronal no longer allows inlays or onlays to be made, teeth for which an all-ceramic crown cannot be made etc.

The natural aspect of the prosthetic restoration resulting from the veneering of ceramic mass depends on the talent and inspiration of the dental technician both in terms of aesthetics and dental morphology, as the art of layering of ceramic masses cannot be surpassed by new emerging technologies.

REFERENCES

1. Bereşescu G. Dinții umani permanenți. Târgu-Mureș: Ed. University Press, 2011.
2. Nelson S.J., Ash M.M. Wheeler's Dental Anatomy, Physiology and Occlusion. 9th. St. Louis: Saunders Elsevier, 2010.
3. Bratu D., Nussbaum R. Bazele clinice și tehnice ale protezării fixe. Ediția a 3-a. București: Ed. Medicală, 2011.
4. Han X, Sawada T, Schille C, Schweizer E, Scheideler L, Geis-Gerstorfer J et al. Comparative Analysis of Mechanical Properties and Metal-Ceramic Bond Strength of Co-Cr Dental Alloy Fabricated by Different Manufacturing Processes. *Materials* (Basel). 2018 Sep 22;11(10):1801. doi: 10.3390/ma11101801. PMID: 30249000; PMCID: PMC6213922.
5. Kessler A, Hickel R, Reymus M. 3D Printing in Dentistry-State of the Art. *Oper Dent*. 2020 Jan/Feb;45(1):30-40. doi: 10.2341/18-229-L. Epub 2019 Jun 7. PMID: 31172871.
6. Spitznagel FA, Boldt J, Gierthmuehlen PC. CAD/CAM Ceramic Restorative Materials for Natural Teeth. *J Dent Res*. 2018 Sep;97(10):1082-1091. doi: 10.1177/0022034518779759. Epub 2018 Jun 15. PMID: 29906206.
7. Alnusayri MO, Sghaireen MG, Mathew M, Alzarea B, Bandela V. Shade Selection in Esthetic Dentistry: A Review. *Cureus*. 2022 Mar 20;14(3):e23331. doi: 10.7759/cureus.23331. PMID: 35464532; PMCID: PMC9015060.
8. McCoy T. Lost wax casting technique for metal crown fabrication. *J Vet Dent*. 2014 Summer;31(2):126-32. doi: 10.1177/089875641403100214. PMID: 25185337.
9. Joda T, Zarone F, Ferrari M. The complete digital workflow in fixed prosthodontics: a systematic review. *BMC Oral Health*. 2017 Sep 19;17(1):124. doi: 10.1186/s12903-017-0415-0. PMID: 28927393; PMCID: PMC5606018.
10. Hickel R, Dasch W, Mehl A, Kremers L. CAD/CAM--fillings of the future? *Int Dent J*. 1997 Oct;47(5):247-58. doi: 10.1002/j.1875-595x.1997.tb00785.x. PMID: 9448805.
11. Miyazaki T, Hotta Y. CAD/CAM systems available for the fabrication of crown and bridge restorations. *Aust Dent J*. 2011 Jun;56 Suppl 1:97-106. doi: 10.1111/j.1834-7819.2010.01300.x. PMID: 21564120.

12. Li KC, Prior DJ, Waddell JN, Swain MV. Comparison of the microstructure and phase stability of as-cast, CAD/CAM and powder metallurgy manufactured Co-Cr dental alloys. *Dent Mater.* 2015 Dec;31(12):e306-15. doi: 10.1016/j.dental.2015.10.010. Epub 2015 Nov 17. PMID: 26597769.
13. Bindl A, Mörmann WH. Marginal and internal fit of all-ceramic CAD/CAM crown-copings on chamfer preparations. *J Oral Rehabil.* 2005 Jun;32(6):441-7. doi: 10.1111/j.1365-2842.2005.01446.x. PMID: 15899023.
14. Al Jabbari YS, Bampagadaki X, Psarris I, Zinelis S. Microstructural, mechanical, ionic release and tarnish resistance characterization of porcelain fused to metal Co-Cr alloys manufactured via casting and three different CAD/CAM techniques. *J Prosthodont Res.* 2019 Apr;63(2):150-156. doi: 10.1016/j.jpor.2018.10.008. Epub 2019 Jan 12. PMID: 30642700.
15. Abrisham SM, Fallah Tafti A, Kheirkhah S, Tavakkoli MA. Shear Bond Strength of Porcelain to a Base-Metal Compared to Zirconia Core. *J Dent Biomater.* 2017 Mar;4(1):367-372. PMID: 28959767; PMCID: PMC5608052.